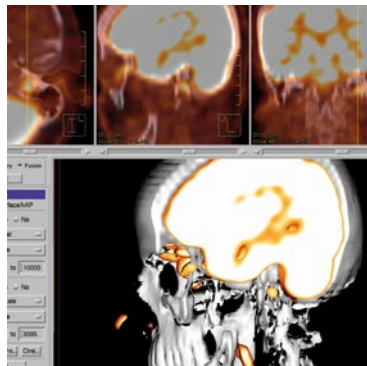
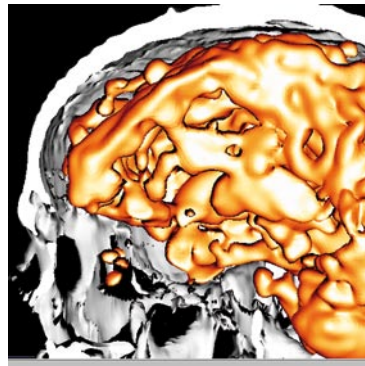


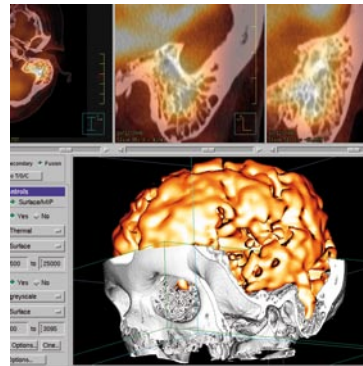
PET/CT FALLBEISPIELE AUS DER PRAXIS IM KÖLN TRIANGLE



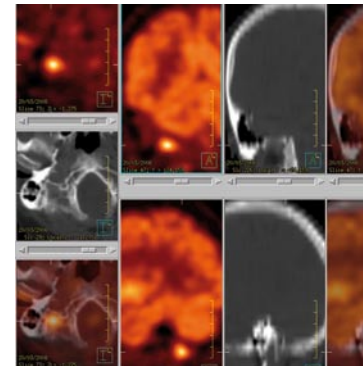
Glomus jugulare Tumor



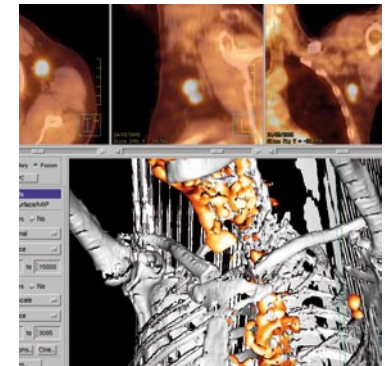
Raumfordernde Arachnoidalzyste



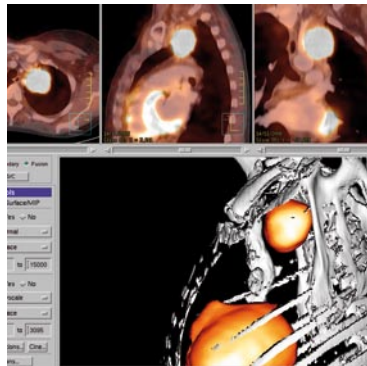
Mastoiditis



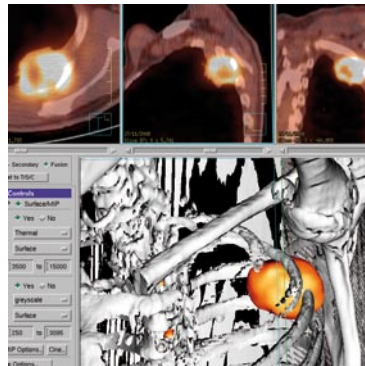Schädelbasismet. als Schwindelursache



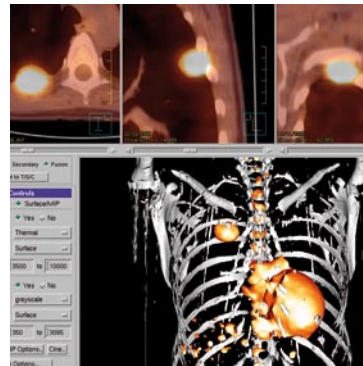
TonsillenCa Rezidiv ax. LK



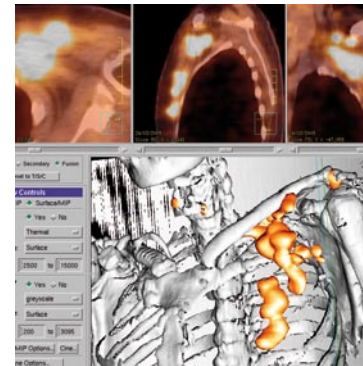
Pancoastumor



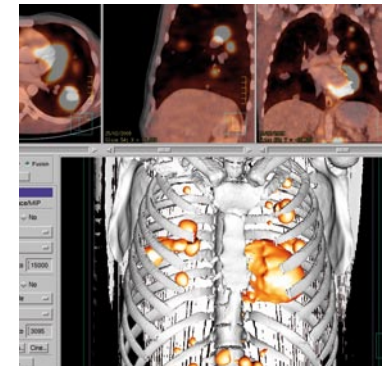
BroCa Thoraxinfiltration



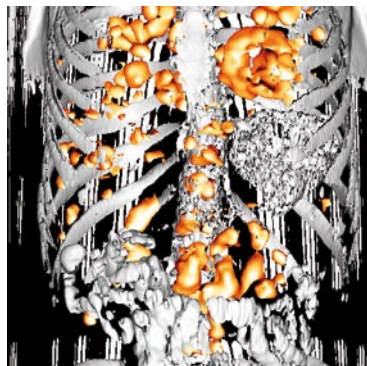
Pleuratumor



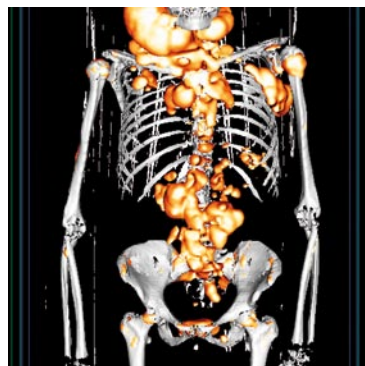MammaCa., ax. Rezidiv



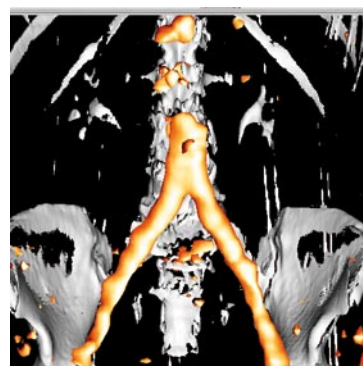
Keimzelltumor Lungenmet.



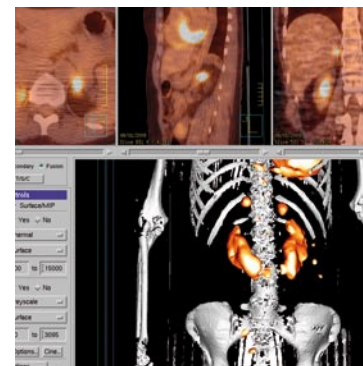
Seminom abd. LK



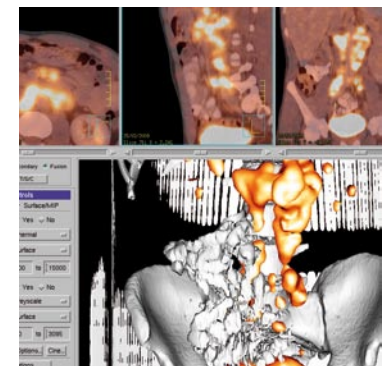
Lymphom



Bypassinfekt als Zufallsbefund

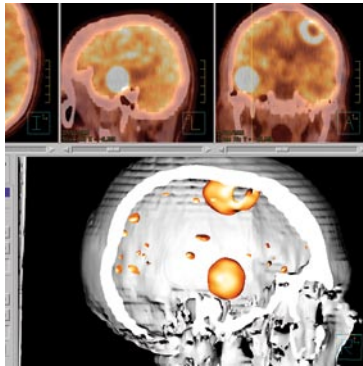


Hufeisenniëre NN-Meta

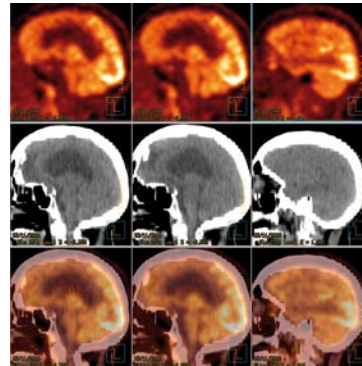


Keimzelltumor abd. LK

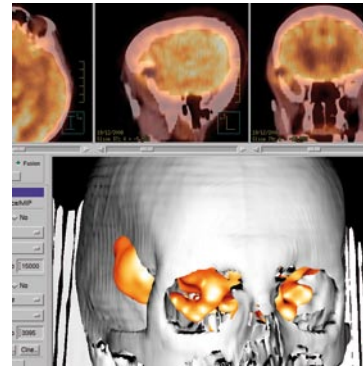
PET/CT FALLBEISPIELE AUS DER PRAXIS IM KÖLN TRIANGLE



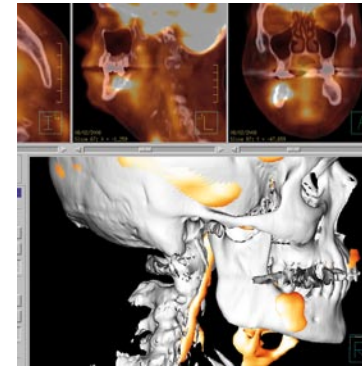
Hirnmetastasen



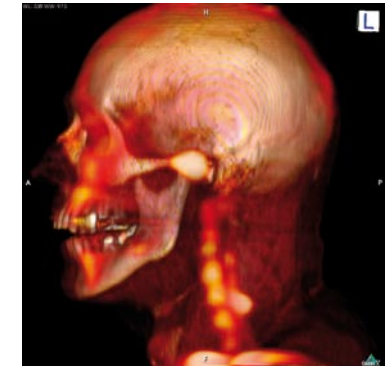M. Pick frontale
Stoffwechsellminderung



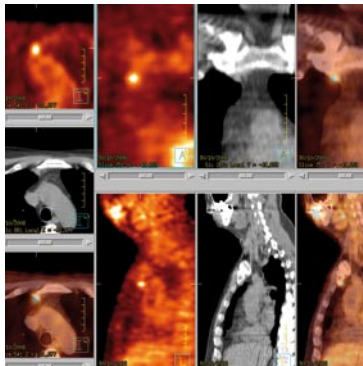
Kalottenmeta re temp



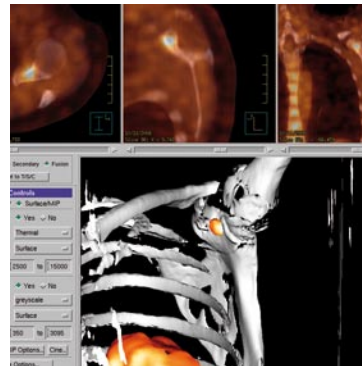
Postrad. Abszess re UK



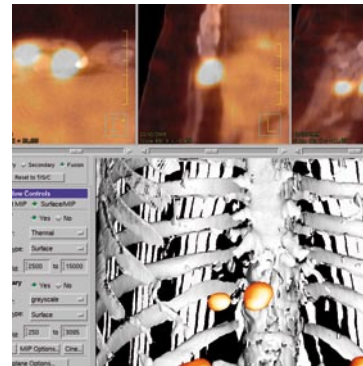
Kiefergelenksarthrose Cerv.
Facettenarthrose



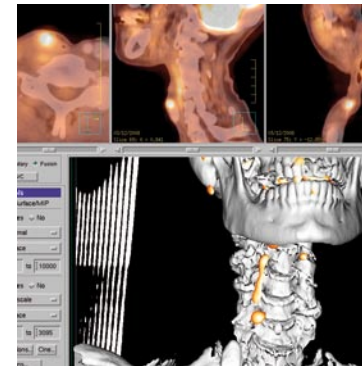
Mal. Melanom, solit. 8mm LK Met.
Zufallsbef., S-100 neg.



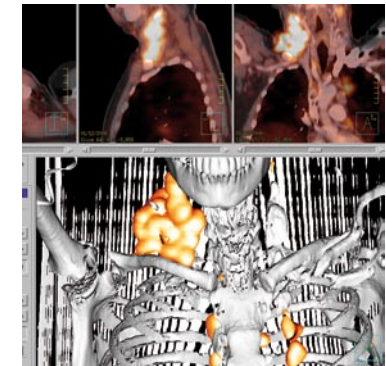
solitäre Skapulamet. MammaCa.,
Tu Markeranstieg



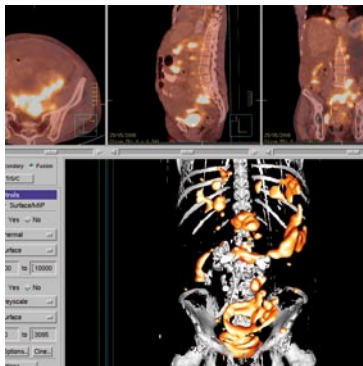
Mamm. Int. LK Meta, MammaCa.,
konv. Staging o.B., Tu Markeranst.



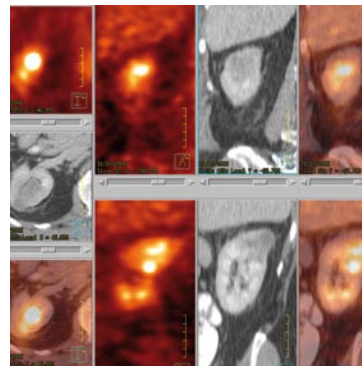
LarynxCa., Rezidiv in Narbe



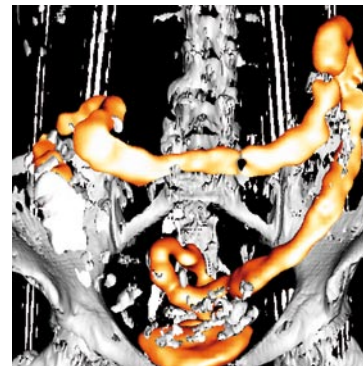
Hodgkin Lymphom



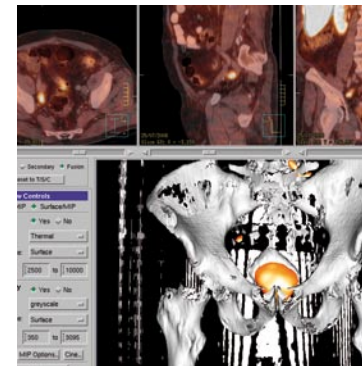
OvarialCa., Peritonealcarcinose



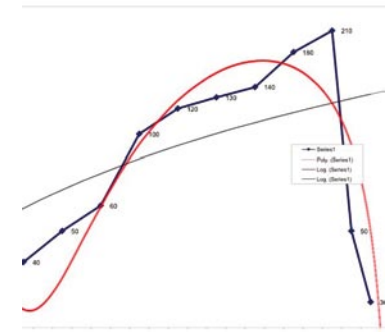
CUP mediast. LK-Metast. UrothelCa



CEA Anstieg Col. ulcerosa



ProstataCa., LK-Rezidiv re, PSA 1,8



PSA Verlauf nach OP, PSA Abfall auf NADIR